

# Boston 2.0 Criteria for Cerebral Amyloid Angiopathy

## Update in Medicine

Juan Antonio Sotelo-Ramirez, MD.<sup>1</sup>, Amado Jiménez-Ruiz, MD.<sup>1</sup>, Juan Carlos Ayala-Alvarez, MD.<sup>1</sup>,  
Iván Roque-Sánchez, MD.<sup>2</sup> and José Luis Ruiz-Sandoval, MD.<sup>1</sup>

<sup>1</sup> *Stroke & Cerebrovascular Disease Clinic. Neurology Department, Hospital Civil de Guadalajara "Fray Antonio Alcalde", Jalisco, México.*

<sup>2</sup> *Faculty of Medicine, Centro Universitario de Ciencias de la Salud, Universidad de Guadalajara, Jalisco, México.*

**Reception date of the manuscript:** 29/September/2024

**Acceptance date of the manuscript:** 20/December/2024

**Publication date:** 02/January/2025

**DOI:** 10.5281/zenodo.14675943

**Creative Commons:** This work is licensed under a Creative Commons Attribution-NonCommercial-NoDerivatives 4.0 International License.

---

### KEY POINT

Cerebral amyloid angiopathy is a common small vessel disease presenting in elderly patients involving amyloid-deposition in the cerebral vasculature, contributing to intracerebral hemorrhage and cognitive impairment. Updated diagnostic criteria are essential for work-up and management.

**Keywords**—Cerebral amyloid angiopathy, Stroke, Intracerebral hemorrhagic stroke, Cognitive impairment, Dementia

---

### PUNTOS CALVE

#### Criterios de Angiopatia Amiloide Cerebral - Boston 2.0

La angiopatía amiloide cerebral es una enfermedad común de los vasos pequeños que se presenta en pacientes de edad avanzada y que implica depósito de amiloide en la vasculatura cerebral, lo que contribuye a la hemorragia intracerebral y al deterioro cognitivo. Los criterios diagnósticos actualizados son esenciales para el estudio y la gestión.

**Palabras clave**—Angiopatia amiloide cerebral, Ictus, Hemorragia intracerebral, Deterioro cognoscitivo, Demencia

We present a brief, updated review, and comparison between the 2010 modified Boston and the recently published Boston 2.0 criteria (Table 1). Essential changes include and integrate specific characteristics such as MRI findings (Figure 1) and previous medical history.

Cerebral amyloid angiopathy (CAA) is a cerebrovascular disease affecting predominantly the elderly population characterized by the deposition of amyloid- in the cerebral arteries. The main clinical manifestations of this condition include lobar hemorrhage, cognitive impairment, and episodes of transient neurological dysfunction (amyloid spells).<sup>1-3</sup>

The updated diagnostic criteria add subarachnoid hemorrhage, cortical superficial siderosis, and white matter lesions (perivascular spaces in centrum semiovale or white matter hyperintensities in a multi-spot pattern).<sup>1</sup> Definite diagnosis still includes a full brain post-mortem pathological examination.

To be classified as a probable diagnosis, the presence in T2\* weighted imaging sequence in MRI of at least two hemorrhages can be a subarachnoid convexity hemorrhage and/or superficial cortical siderosis without requiring other entities. A possible diagnosis can be defined as a single lobar hemorrhage or white matter hyperintensity features, both stages, with the patient aged 50 years and older.<sup>1</sup>

In conclusion, a single subarachnoid hemorrhage, cortical superficial siderosis, or CAA-white matter lesions are classified for possible diagnosis. CAA-related white matter lesions, such as dilated perivascular spaces, may appear sooner in disease progression and allow earlier diagnosis and treatment.<sup>1,2</sup>

## FUNDING

No external funding was obtained for the realization of this work.

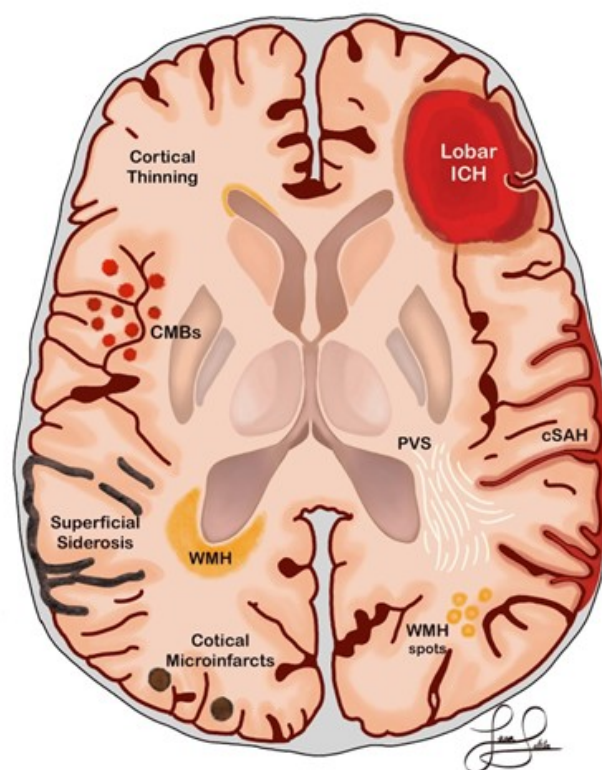
## CONFLICTS OF INTEREST

There is no conflict of interest to disclose.

## REFERENCES

[1] Charidimou, A., Boulouis, G., Frosch, M. P., Baron, J.-C., Pasi, M., Albucho, J. F., Banerjee, G., Barbato, C., Bonneville, F., Brandner, S., Calviere, L., Caparros, F., Casolla, B., Cordonnier, C., Delisle, M.-B., Deramecourt, V., Dichgans, M., Gokcal, E., Herms, J., Greenberg, S. M. (2022). The Boston criteria version 2.0 for cerebral amyloid angiopathy:

**Contact data:** Juan Antonio Sotelo-Ramirez, MD., Stroke & Cerebrovascular Disease Clinic. Neurology Department, Hospital Civil de Guadalajara "Fray Antonio Alcalde". Coronel Calderón No. 777, Col. El Retiro, Guadalajara, Z.C., Jalisco, México., Phone number: (+52) 33 3942 4400, ext. 4400, email: antonio.sotelo.r08@gmail.com



**Figure 1:** Brain MRI findings in Cerebral Amyloid Angiopathy. (Modified from Carmona-Iragui *et al.*, 2019 and Charidimou *et al.*, 2017 4). Convexal subarachnoid hemorrhage (cSAH), cortical microinfarcts, cortical superficial siderosis, lobar intracerebral hemorrhage (ICH), cortical thinning, dilated perivascular spaces (PVS), white matter hyperintensities (WMH), and cortical microbleeds (CMBs).

A multicentre, retrospective, MRI-neuropathology diagnostic accuracy study. *The Lancet Neurology*, 21(8), 714–725. [https://doi.org/10.1016/S1474-4422\(22\)00208-3](https://doi.org/10.1016/S1474-4422(22)00208-3)

- [2] Perosa, V., Oltmer, J., Munting, L. P., Freeze, W. M., Auger, C. A., Scherlek, A. A., van der Kouwe, A. J., Iglesias, J. E., Atzeni, A., Bacskai, B. J., Viswanathan, A., Frosch, M. P., Greenberg, S. M., van Veluw, S. J. (2022). Perivascular space dilation is associated with vascular amyloid- accumulation in the overlying cortex. *Acta Neuropathologica*, 143(3), 331–348. <https://doi.org/10.1007/s00401-021-02393-1>
- [3] Carmona-Iragui, M., Videla, L., Lleó, A., Fortea, J. (2019). Down syndrome, Alzheimer disease, and cerebral amyloid angiopathy: The complex triangle of brain amyloidosis. *Developmental Neurobiology*, 79(7), 716–737. <https://doi.org/10.1002/dneu.22709>
- [4] Charidimou, A., Boulouis, G., Gurol, M. E., Ayata, C., Bacskai, B. J., Frosch, M. P., Viswanathan, A., Greenberg, S. M. (2017). Emerging concepts in sporadic cerebral amyloid angiopathy. *Brain*, 140(7), 1829–1850. <https://doi.org/10.1093/brain/awx047>
- [5] van Rooden, S., van der Grond, J., van den Boom, R., Haan, J., Linn, J., Greenberg, S. M., van Buchem, M. A. (2009). Descriptive analysis of the Boston criteria applied to a Dutch-type cerebral amyloid angiopathy population. *Stroke*, 40(9), 3022–3027. <https://doi.org/10.1161/STROKEAHA.109.554378>

Modified Boston Criteria (2010) <sup>5</sup>	Boston Criteria 2.0 <sup>2</sup>
<b>Definite CCA</b>	
Full brain post-mortem examination demonstrating: - Lobar, cortical, or cortical-subcortical hemorrhage  - Severe CCA with vasculopathy - Absence of another diagnostic lesion	Full brain post-mortem examination demonstrating: - Spontaneous intracerebral hemorrhage, transient focal neurological episodes, convexity subarachnoid hemorrhage, or cognitive impairment or dementia - Severe CAA with vasculopathy - Absence of another diagnostic lesion
<b>Probable CCA with supporting pathology</b>	
Clinical data and pathological tissue (evacuated hematoma or cortical biopsy) demonstrating: - Hemorrhage  - Some degree of CAA in specimen - Absence of another diagnostic lesion	Clinical data and pathological tissue (evacuated hematoma or cortical biopsy) demonstrating: - Presentation with spontaneous intracerebral hemorrhage, transient focal neurological episodes, convexity subarachnoid hemorrhage or cognitive impairment or dementia - Some degree of CAA in specimen - Absence of another diagnostic lesion
<b>Probable CCA</b>	
- For patients aged 55 and older - Appropriate clinical history - MRI criteria - Multiple hemorrhages restricted to lobar, cortical, or cortical-subcortical regions (cerebellar hemorrhages allowed) without another cause, or - A single lobar, cortical, or cortical-subcortical hemorrhage and focal (three or fewer sulci) or disseminated (more than three sulci) cortical superficial siderosis without another cause	- For patients aged 55 and older - Presentation with spontaneous intracerebral hemorrhage, transient focal neurological episodes, or cognitive impairment or dementia (clinical data) - MRI criteria - Demonstrates either: — At least two of the following strictly lobar hemorrhagic lesions on T2*-weighted MRI, in any combination: intracerebral hemorrhage, cerebral microbleeds, or foci of cortical superficial siderosis (multiple distinct foci are counted as independent hemorrhagic lesions) or convexity subarachnoid hemorrhage (multiple distinct foci are counted as independent hemorrhagic lesions); or — One lobar hemorrhagic lesion plus one white matter feature (severe perivascular spaces in the centrum semiovale or white matter hyperintensities in a multispot pattern) — Absence of: — Any deep hemorrhagic lesion on T2*-weighted MRI; and — Hemorrhagic lesion in cerebellum not counted as either lobar or deep hemorrhagic lesion — Other cause of hemorrhagic lesions
<b>Possible CCA</b>	
- For patients aged 55 and older - Appropriate clinical history - MRI criteria  - A single lobar, cortical, or cortical-subcortical hemorrhage without another cause, or Focal or disseminated cortical superficial siderosis without another cause	- For patients aged 55 and older - Presentation with spontaneous intracerebral hemorrhage, transient focal neurological episodes, or cognitive impairment or dementia (clinical data) - MRI criteria - Demonstrates either: — One strictly lobar hemorrhagic lesion on T2*-weighted MRI, intracerebral hemorrhage, cerebral microbleeds, or foci of cortical superficial siderosis or convexity subarachnoid hemorrhage; or — One white matter feature (severe perivascular spaces in the centrum semiovale or white matter hyperintensities in a multispot pattern) - Absence of — Any deep hemorrhagic lesion on T2*-weighted MRI; and hemorrhagic lesion in cerebellum not counted as either lobar or deep hemorrhagic lesion — Other cause of hemorrhagic lesions — Hemorrhagic lesion in cerebellum not counted as either lobar or deep hemorrhagic lesion

**TABLE 1:** COMPARISON BETWEEN MODIFIED BOSTON 2010 AND BOSTON 2.0 DIAGNOSTIC AND CLASSIFICATION CRITERIA. **CAA:** CEREBRAL AMYLOID ANGIOPATHY; **MRI:** MAGNETIC RESONANCE IMAGING.